

# NEWER MRI TECHNIQUES



# HISTORY

- In 1973, Paul Lauterbur published the first nuclear magnetic resonance image.
- Prof Peter Mansfield (Nottingham University, UK) was awarded Nobel in 2003 for his discoveries in MRI ( with Prof Paul C Lauterbur )



- Magnetic resonance imaging was developed from knowledge gained in the study of nuclear magnetic resonance.
- In early years the technique- referred to as nuclear magnetic resonance imaging (**NMRI**).
- However, it is now referred to simply as **MRI**



# BASICS OF MRI


- Based on complex interaction between
  - Protons in human body
  - Magnetic field
  - Radiofrequency energy



# BASICS OF MRI

- Object to be imaged is placed in a powerful, uniform magnetic field, ( $B_0$ ).
- The spins of atomic Nuclei are characterized by
  - Nuclei align parallel or anti-parallel to  $B_0$
  - **Precession** : Wobbling sort of motion undergone by spinning object ,frequency of precession is called the Larmor frequency.



- Brief exposure to pulses of electromagnetic field  $B_1$  (RF pulse at LARMOR frequency) at  $90^\circ$  to  $B_0$ .
- As the RF pulse continues, the spins change lower energy to higher energy state.
- This leads to “tipping” of the net magnetization toward the transverse plane.
- Spins phases are coherent (aligned with each other). 

- When  $R_f$  is shut off - Spins lose their phase coherence & the signal decays. This process is called **transverse relaxation** (because it happens while the spins are in the transverse plane).
- Characterized by an exponential time constant,  $T_2$  (tens to hundreds of ms).
- $T_1$  is time taken by protons to return to normal equilibrium (**longitudinal relaxation**).



## ○ SPIN ECHO

- TR (Repetition Time ): Interval between Rf pulses.
- TE (Echo time): Time between Rf pulse & signal reception.





# BASIC IMAGING SEQUENCES

- T 1 WI
- T 2 WI
- T2 \* WI
- GRADIENT ECHO
- FLAIR
- STIR



# IMAGING CHARACTERISTICS

- T1 WI: TR & TE short  
T2 WI: TR & TE long
- T1 WI: **Dark - Water, CSF, edema, Calcium**  
(can be paradoxically bright because of crystalline structure of calcium)  
**Bright - Lipid ,Gadolinium,subacute blood, protein, Mn, melanin**
- T2 WI: **Dark - Calcium, bone**  
**Bright - CSF, water, edema**



## ○ **ECHOPLANAR IMAGING:**

- Single excitation used to collect all multiple images (40ms)
- Used in applications highly sensitive to even minor proton movement.

### **USED IN:**

- ❖ Diffusion MR
- ❖ Perfusion MR
- ❖ Functional MR

## **GRADIENT ECHO**

- An excitation pulse with a flip angle lower than  $90^\circ$
- No  $180^\circ$  rephasing pulse
- TR is very short and scan time very less (sec)
- Visualise hemosiderin and ferritin

### **-USED IN**

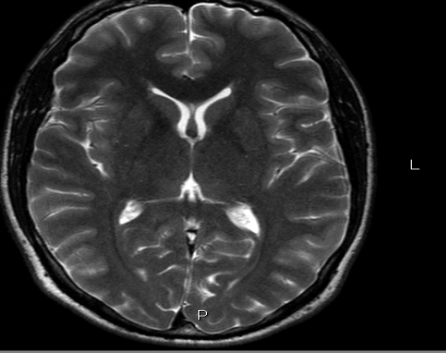
- MRA
- CISS  
(Constructive interference in steady state)



# *T1-WEIGHTED MRI*

- Use a (GRE) sequence - short  $TE$  and  $TR$ .
- Due to the short repetition time ( $TR$ ) this scan can be run very fast allowing the collection of high resolution 3D datasets.
- Basic types of MR , contrast used, is a commonly run clinical scan.
- The  $T1$  weighting can be increased (improving contrast) with the use of an inversion pulse as in an *MP-RAGE sequence*.
- Provide good gray matter/white matter contrast.  
**(ANATOMY)**

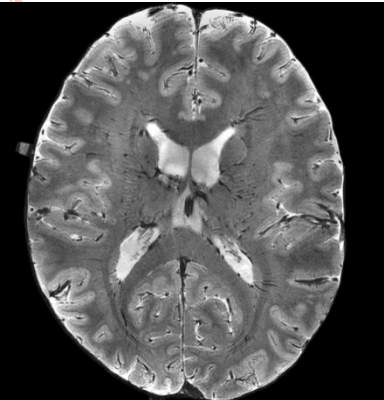




## ***T2-WEIGHTED MRI***

- Use a Spin Echo (SE) -long  $T E$  and  $T R$ .
- SE less susceptible to inhomogeneity in the magnetic field.
- Well suited to edema as they are sensitive to water content (edema is characterized by increased water content): **PATHOLOGY**





## **$T^*2$ -WEIGHTED MRI**

- $T^*2$  - (GRE) sequence- long  $TE$  and long  $TR$ .
- Gradient echo sequence used.
- Does not have the extra refocusing pulse used in spin echo
- So it is subjected to additional losses above the normal  $T2$  decay (referred to as  $T2'$  ), these taken together are called  $T^*2$ .
- Increase contrast for certain types of tissue, such as venous blood



# FLUID ATTENUATED INVERSION RECOVERY (FLAIR)

- Sequence used to null signal from fluids. E.g. CSF so as to bring out lesions at fluid-parenchyma interface
- Choosing the inversion time TI (the time between the inversion and excitation pulses), the signal from any particular tissue can be suppressed
- **CLEAR FLUID in a CLOSED SPACE will be suppressed**
- **FAST FLAIR:** Fast spin echo plus flair



# USES

1. **For periventricular & subcortical abnormalities:** (Cortical & juxtacortical multiple sclerosis lesions, degenerative diseases).
2. **In seizure disorders (e.g MTS):**
  - Sensitive for detecting signal abnormalities demonstrating size asymmetry & abnormal signal within the atrophied hippocampus.





3. **Differentiating epidermoid from arachnoid cyst** - Signals of epidermoid being similar to brain parenchyma ,arachnoids cyst signal suppressed.
  
5. ***Diffuse axonal injury***: White matter lesion volume can be quantitatively assessed.



## **5 STROKE :**

**HYPERINTENSITY ON FLAIR AS EARLY AS 4-6 HRS AFTER ICTUS & TI, T2 - NORMAL.**

**SLOW-FLOWING ARTERIES ARE DEPICTED BY FLAIR AS HYPERINTENSITIES AGAINST DARKER BRAIN TISSUE, LEADING TO THE "HYPERINTENSE VESSELS SIGN" (HVS).**

**HVS IS A REVERSIBLE SIGN, WITH HYPOPERFUSION WITHOUT INFARCTION.**



# DISADVANTAGE

- Artfactual increased signal in and around CSF spaces, limits its role in posterior fossa.
- Incomplete nulling of CSF signals due to CSF inflow effects produces imaging artifacts.
  - Areas of prominent CSF pulsatility, such as inferiorly located sections and those containing foramina of the CSF ventricular system.
  - May not detect lesions located in the brain stem.
- Poor lesion contrast may be present
  - In the basal ganglia & posterior fossa (particularly MS plaques), & the inability to clearly depict cystic lesions.



# FAT SUPPRESSION SEQUENCE

- Short tau inversion recovery (**STIR**) -Using adequate inversion time (100-150ms) signal from fat is suppressed while it becomes very sensitive to change in water content.
- Uniform & consistent fat suppression and excellent T2-like contrast when long repetition times are used.

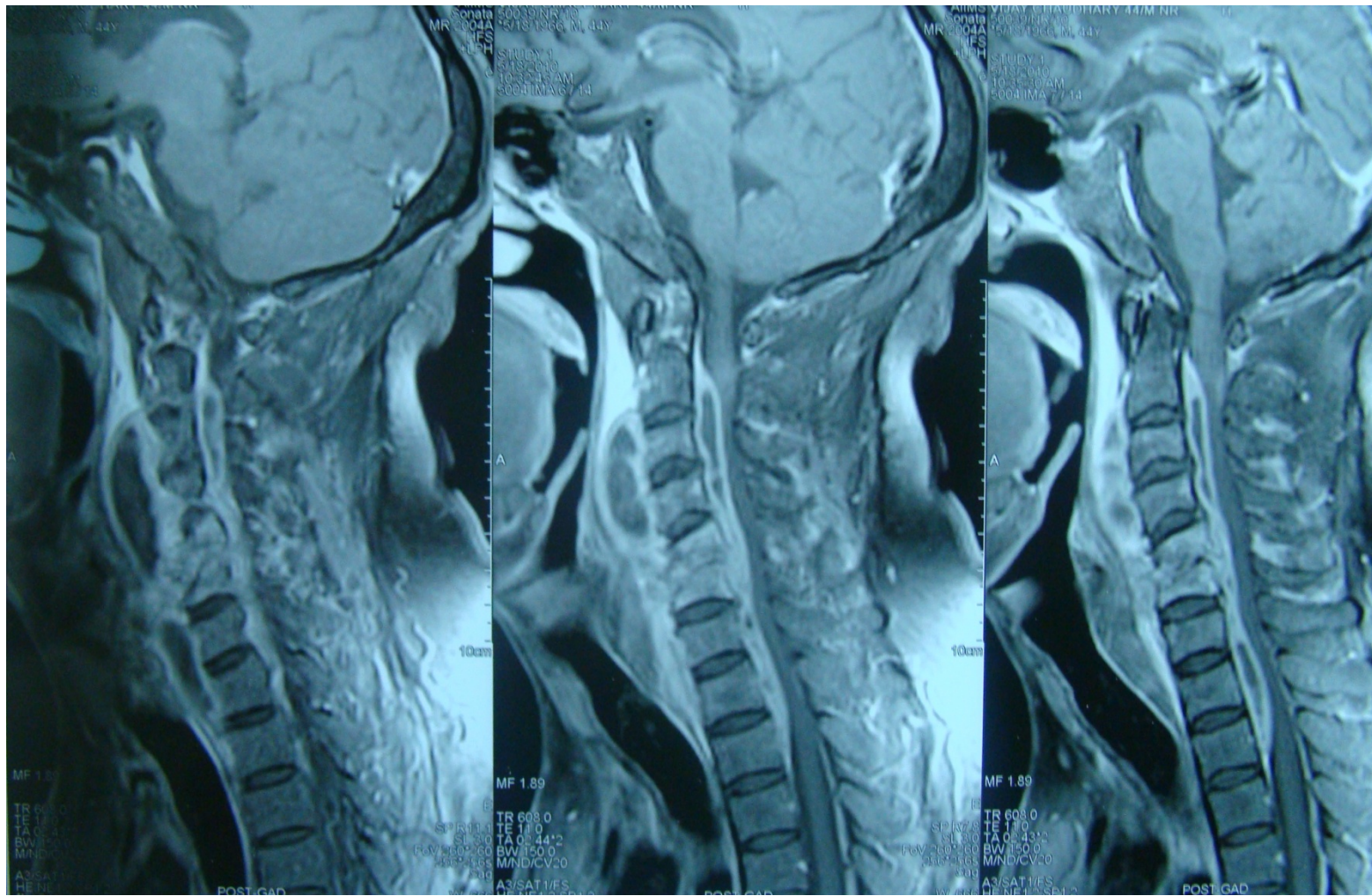


# USES

1. Lesions in the optic nerve can be visualized  
e.g. traumatic, demyelinating.
2. Metastasis to vertebral body in fatty marrow
  - These can be missed on T2.
3. Useful for fractures of vertebral body.
4. Musculoskeletal imaging.
5. Useful in carpal tunnel syndrome .  
Carpal tunnel syn. – flattened median nerve &  
signal from denervated muscles



# MRI FAT SAT



# NEWER MRI TECHNIQUES

## Factors in development of Newer Techniques

- High Strength of Magnet ( upto 7.5 T)
- Improved Gradient Coil
- Software Development
- Understanding of molecular biology of lesion



# NEWER MRI TECHNIQUES

- Improvement Resolution : e.g. MPRAGE, CISS
- Short Scanning Time: e.g. Echo planner imaging
- Functional Imaging: e.g. FmRI, PWI(ASL)
- Microstructural imaging : e.g. DWI, DTI
- Biochemical Structures: MRS
- Fusion images : PET MR
- Tissue contrast : SWI
- Intraoperative/ Interventional MR





# CONSTRUCTIVE INTERFERENCE IN STEADY STATE (CISS)

- Heavily weighted T2 sequence with a strong and constant signal for cerebrospinal fluid.
- 3-D gradient technique, where signal from brain parenchyma is suppressed.
- Fluid appears bright.



# USES

1. Detailed images of the cerebellopontine angle, internal auditory canals, cranial nerves.
2. PERIOP. Evaluation in endoscopic approach to the intraventricular cysts, suprasellar cysts & the cyst associated with hydrocephalus, located in the midline.
3. 3D CISS MR imaging with MPR (multiplanar reconstruction)-In detection of NVC in patients with trigeminal neuralgia.



**4. In evaluation of brachial plexus injuries, if root avulsion is suspected, CISS is used to perform 3-D MR myelography.**

- Uniform signal intensity and high contrast between CSF & neural structures are obtained.
- Enabled detection of meningoceles, avulsed or intact nerve roots, dural sleeve abnormalities & dural scars.
- Evaluation of nerve root integrity -89% sensitivity, 95% specificity.



## 5. Used for evaluation of CSF rhinorrhea (MR cisternography)

- The sensitivity & specificity of the MR method (88.9% & 95.1%) is higher compared with CT cisternography (77.8% & 87.8%).
- Less than 2mm, multiple defects.
- Noninvasive.
- Administration of contrast & agent is no longer necessary.



# SWI SEQUENCES

- SWI measures susceptibility differences between tissues, offering a new form of contrast enhancement.
- When phase effects are caused by small pixel-sized objects, signals from substances with different magnetic susceptibilities can become out of phase at long echo times (TE) compared to neighbouring tissues.
- SWI is combination of magnitude images and phase images merged into a new image.



# SWI SEQUENCES

- In the brain, the goal of an SWI exam would be to look for changes in venous vasculature, microbleeds, and changes in local iron content.
- SWI may even serve as an important morphological scan to go along with T1-weighted images for functional MRI studies as well.
- The imaging of venous blood with SWI is called blood-oxygen-level dependent (BOLD) technique.



# USES

1. HEMORRHAGES IN VARIOUS LESION

2. TRAUMATIC BRAIN INJURY- DIFFUSE AXONAL INJURY

3. STROKE - IN THE SWI IMAGE, YOU ARE SEEING EVIDENCE OF DRAMATIC CHANGES IN OXYGEN SATURATION AND MAYBE OTHER SOURCES OF SUSCEPTIBILITY. WE CAN SEE THE SOURCE OF THE STROKE AND MAYBE THE VASCULAR TERRITORY AFFECTED.



#### **4. In Brain Tumors :**

- Understanding the angiographic behaviour of lesions both from the perspective of angiogenesis and micro-hemorrhages.
- Leads to better contrast in detecting tumor boundaries and tumor hemorrhage

#### **5. Multiple sclerosis**

- SWI adds by revealing the venous connectivity in some lesions and presents evidence of iron in some lesions.

#### **6. Vascular dementia and cerebral amyloid angiopathy (CAA)**

#### **7. Sturge-Weber disease:**





# DIFFUSION MRI

- Based on echo planar imaging.
- Diffusion of contrast depends on Brownian motion of free proton.
- Restriction of motion appears as high signal intensity.
- Water molecules that are not “restricted” will have greater net diffusion over a given period of time than water molecules surrounded by cell organelles membranes, large proteins etc.
- High signal is inversely proportional to ADC.



# *Brain Tumors on DWI*

- Highly cellular tumors such as lymphoma, medulloblastoma and meningioma have a lower ADC than the brain parenchyma.
- **Viable tumor shows normal-high SI on DWI, decreased ADC**
- **In areas of tumor necrosis, low SI on DWI, increased ADC.**



# USES

- DWI is highly sensitive in identifying hyperacute(0-6hr) & acute infarction(6-24hr), within minutes of occlusion, while conventional MRI takes 6-10 hours. MRI can help to define :
  - acutely ischemic region (DWI)
  - the tissue at risk for further ischemia (PWI)
  - vascular anatomy (MRA)



- Abscess shows :  
decreased diffusion  
& increased signal  
intensity.
- As Abscess cavity:  
numerous WBCs &  
proteinaceous fluid  
with high viscosity.
- Restricted  
diffusion -low ADC  
values high signal  
intensity on DWI.




- Necrotic or cystic tumors  
**(low SI, high apparent  
diffusion coefficient  
(ADC))**
  - In contrast, the cystic or necrotic portions of brain tumors : less cellular and have less viscous fluid consistency.
  - Tumors show low signal intensity on DWI and higher ADC values.



# • DIFFERENTIATION OF THE ARACHNOID CYST VS EPIDERMOID

**ARACHNOID CYST -LOW SIGNAL INTENSITY**

**EPIDERMOID CYSTS - HIGH SIGNAL**



**a, Echo-planar DW imaging reveals the tumor as a sharply hyperintense lesion (arrows) relative to the brain and CSF.**


**b, ADC map shows that the intensity of the tumor is similar to that of surrounding brain tissue but much different from that of CSF.**

# DIFFUSION TENSOR IMAGING

- Special diffusion technique capable of demonstrating white matter tracts and their relationship to lesions.
- **BASIS: Detection of preferential motion of water along white matter fiber tracts.**
- **FRACTIONAL ANISOTROPY(FA)-ALIGNMENT OF INTEGRITY**
- Tensor is a map of directional vectors in 3d space



# USES

- Intraoperative Neuronavigation Using Diffusion Tensor Tractography e.g. Tract, optic radiation. Resection of a deep tumor adjacent to the Corticospinal tract.
  - This enables researchers to make brain maps of fiber directions to examine the connectivity of different regions in the brain.
  - To examine areas of neural degeneration & demyelination in diseases like Multiple Sclerosis (**white matter diseases**).
- 



# PERFUSION MRI

- Perfusion MRI techniques are sensitive to microscopic levels of blood flow.
- **CONTRAST PASSAGE CAUSES SIGNAL LOSS**
- Gadolinium causes loss of MR signal,
  - most marked on T2\* (gradient echo) - weighted
  - T2 (spin echo) weighted sequences –
  - caused by the magnetic field distorting effects of paramagnetic substances.



- Passage of contrast causes drop in signal intensity –calculate rate of change of  $T2^*$ 
  - *LINEARLY PROPORTIONAL TO CONTRAST CONCENTRATION.*
- Contrast concentration time course in each voxel is analysed.
- Data is analysed to calculate
  - Relative cerebral blood volume (rCBV).
  - Mean transit time (contrast arrival time to time to peak contrast concentration) – MTT.
  - Relative cerebral blood flow (rCBF).



# USES

Infarction: Delay in mean transit time, reduction in cerebral blood volume, reduced cerebral blood flow.



- Perfusion MRI may be a valuable tool for characterizing and monitoring ischemia in *Moya Moya* disease.
- Has potential role comparable to SPECT in the evaluation of *Moya Moya* disease.



# MAGNETIC RESONANCE ANGIOGRAPHY

1. Time of Flight MR Angiography
2. Phase Contrast MR Angiography
3. Contrast Enhanced MR Angiography



# 1. TIME-OF-FLIGHT SEQUENCES

- 2D & 3D "flow-related enhancement"
- where most of the signal on an image is due to blood which has recently moved into that plane.
- Vascular flow map rather than anatomic map.



## 2. PHASE CONTRAST MRA :

- Utilizing the change in the phase shifts of the flowing protons. two data sets with a different amount of flow sensitivity are acquired.
- longer acquisition time than TOF.
- It can produce anatomic information ,velocity & direction of blood flow.
- **Selective venous & arterial images can be obtained.**



### 3. ADMINISTRATION OF A PARAMAGNETIC CONTRAST AGENT (GADOLINIUM) MRA

- Standard for extracranial vascular MRA. During bolus infusion TOF sequence is used.
- Better evaluates intracranial aneurysms and post coiling follow up of aneurysm.
- Also good in delineating draining veins and nidus of AVM






# USES

1. Excellent for screening of stenosis, occlusion, dissections in carotids of neck.
2. Useful for noninvasive diagnosis of intracranial aneurysm/vascular malformations.
3. ICA & initial branches of ACA, MCA & PCA can be assessed.



# DRAWBACKS

- Spatial resolution is poor compared to conventional angiography. Detection of small vessel diseases is problematic.
  - MRA is also less sensitive to slow flowing blood and may not reliably differentiate complete from near- complete occlusion.
  - Motion artifacts by patient or anatomic structure may distort image.
  - Signal loss in complex flow.
- 

# MAGNETIC RESONANCE SPECTROSCOPY

- Measure the levels of different metabolites in body tissues-Provides 'metabolic signature' of tissue.
- Studying the chemical composition of living tissue *NON INVASIVELY*.
- Chemical elements used: hydrogen, phosphorus, carbon.
- **Proton (1H) resonance is nowadays the method most frequently used in neuro spectroscopy.**
  - Most abundant atom in the human body nucleus.
  - Emits the most intense radiofrequency signal, when in an external magnetic field.



- Chemical shift is measured in Hz or parts per million (ppm). The preferred unit is ppm.
- **NAA**                      **2.0 ppm**
- **Cr**                              **3.0**
- **Cho**                            **3.2**
- **Lac**                            **1.3**
- **Lip0**                        **0.8-1.4**



- ***N-acetyl aspartate*** : NEURONAL INTEGRITY
- ***Choline*** : CELL TURNOVER
- ***Myoinositol*** –ASTROCYTE MARKER
- ***Amino acids*** are encountered in brain abscesses.  
Astrocyte marker
- ***Lipids***-always pathological-The presence of ***lipids*** is related to necrotic processes.
- ***Creatine***-marker of intact brain metabolism
- ***lactate***: ANAEROBIC GLYCOLYSIS



# USES

- **Differential diagnosis of focal brain lesions** (neoplastic & non-neoplastic diseases).
- **Gliomas : Decreased intensity of the N-acetyl aspartate peak and increased choline occur.**
- Lactate peaks may be found ,independent of their malignancy grade, indicating hypoxia.
- Most non- glial tumors have little or no NAA.
- High grade glioma – exhibit higher Cho/Cr and Cho/NAA ratio.
- ***Multi- voxel spectroscopy is best to detect infiltration of malignant cells beyond the enhancing margins of tumors.***



# TUMOR RECURRENCE VS. RADIATION EFFECTS

- Elevated choline is a marker for recurrent tumor.
- Radiation change generally exhibits low NAA, creatine & choline .
- If radiation necrosis is present, the spectrum may reveal elevated lipids & lactate.



# *INFLAMMATORY & INFECTIOUS PROCESSES*

- Tuberculosis
- ❖ MRS shows a broad lipid peak & occasionally a lactate peak, with a decrease or absence of N-acetyl aspartate & slight increase of choline.





# *PYOGENIC ABSCESS*

- Amino acid peaks, especially succinate, acetate.-due to the great quantity of hydrolytic enzymes produced by bacteria.
- Lactate peak-due to anaerobic metabolism
- N-acetyl aspartate, creatine and choline peaks are not detected.



# *ISCHEMIC LESIONS*

- Early appearance of a lactate peak. –anaerobic metabolism
- Decrease of N-acetyl aspartate-neuronal loss
- Slight increase of choline-membrane degradation



# FUNCTIONAL MRI

- Functional MRI (fMRI) measures signal changes in the brain that are due to changing neural activity.
- Scanning low resolution but at a rapid rate (typically once every 2-3 seconds).
- Increases in neural activity cause changes in the MR signal via  $T2^*$  changes.
- **BOLD (blood-oxygen-level dependent):** imaging examines changes in local tissue oxygenation to exploit the magnetic property changes of Hb as an intrinsic contrast agent.



- Activity increases demand for O<sub>2</sub>, vascular system over compensates for this, increasing the amount of oxygenated Hb relative to deoxygenated Hb.
- **Because deoxygenated Hb attenuates the MR signal (less paramagnetic), the vascular response leads to a signal increase.**
- Change in intensity at 1.5T images are repeatedly acquired at same location over course of stimulus using EPI sequence.



INITIAL 10 PRE-STIMULATION (BASELINE) IMAGES  
ARE FOLLOWED BY 10 ACTIVATION IMAGES (LEFT  
HAND STIMULATION) AND 10 POST-STIMULATION  
IMAGES



○ **LOCALISES:**

1. Visual cortex

2. Motor cortex

3. Somatosensory cortex

4. Broca's area of speech

5. language-related activities.

6. Memory area



# ADVANTAGES OF FMRI

1. Does not require injections of radioactive isotopes, (PET requires it).
2. The total scan time required can be very short, i.e. in the order of 1.5 to 2.0 min per run.



## 1. **ROLE IN NEUROSURGICAL PLANNING:**

- When the presence of a tumor alters the expected location .
- Uncertain function such as association cortex or language-related processes.





## **2. FUTURE ROLE IN PAIN MANAGEMENT**

Identification of cortical areas that are modified by the reduction of pain following pain therapy using fMRI to investigate cortical representations of specific pain types.

## **3. ROLE IN UNDERSTANDING THE PHYSIOLOGICAL BASIS FOR NEUROLOGICAL DISORDERS**

fMRI may contribute to improved precision of seizure localization & understanding of seizure progression & suggests a future direction for investigation.



# INTRAOPERATIVE MRI

- Provides real time image guidance .
- Open magnet design/horizontal flat plane design.
- Patient is wheeled In & out for imaging.
- All anesthesia equipment & microscope has to be MR compatible.



# USES

- For craniotomy- gliomas , especially near eloquent cortex, deep seated.
- For biopsy of deep seated lesions.
- Transsphenoidal surgery : MR used to optimize angle of entry in sella.
  - Intraop normal gland versus tumor can be identified.
  - Resection guided in large tumors with parasellar extension.
- Surgery for Intracranial cysts :



# ADVANTAGES

- Accurate real time localization.
- Increased safety of approach through choice of optimal trajectory.
- Definite intraoperative identification of surrounding structures & their relationship to surgical anatomy.
- Immediate evaluation of extent of resection.
- Monitoring of any intraoperative complication e.g. hemorrhage.




# IMAGE FUSION

- Image fusion (exactly overlapping the images in three dimensional space) bring all of the above information together in the operating room.
- Intra operative image fusion. gives a "road map" showing unique features of the tumor as well as the location of critical structures that is must to preserve speech, walking and other functions.
- MP-RAGE: 3D T1 WT with contrast to make a surgical road map for IMAGE GUIDANCE SURGERY.



# CINE PHASE CONTRAST MRI

- Can demonstrate qualitatively & quantitatively alterations in CSF flow during the cardiac cycle.
  - *Synchronizes MR data acquisition to a motion cycle to enable imaging of moving tissue.*
  - Cine MRI collects image data over many cycles of periodic motion.
  - Used for evaluating cranial & spinal CSF flow.
- 

## USES

1. Physiology of the normal CSF circulation.
2. Pathological CSF flow dynamics in communicating & obstructive hydrocephalus, Chiari malformation, syrinx.
3. Cine MR imaging has been recommended for evaluating the patency of third ventriculostomies.
4. Cerebrospinal Fluid Flow After Endoscopic Aqueductoplasty.



- Cine MRI: On the left, no posterior flow (arrow) in a patient before decompression of their Chiari I malformation
- Cine MRI, return of CSF flow represented by the white space behind the cerebellar tonsils after decompression (white arrow)





# MP-RAGE

- MP-RAGE (magnetization-prepared rapid acquisition with gradient echo):
- Volume Sequence with High Resolution
- Decrease Acquisition time
- Reconstruction is possible
- Useful : - Neuronavigation
  - Gamma Knife Therapy
  - Multiple sclerosis cortical lesions
- Disadvantage- Leptomeningeal enhancement less



# POST CONTRAST MP RAGE

BRONCHOGENIC CA WITH MULTIPLE METS



# MT (MAGNETISATION TRANSFORMATION) AND MTR

- The water with restricted motion is generally conceived as being bound to macromolecules, such as proteins and lipids through a series of hydrogen bonds.
- Hydrated water molecules are slowed down by extensive interactions with the protons in the local macromolecules and hence magnetic field inhomogeneities are created that lead to wider resonance frequency spectrum.
- MT is believed to be a nonspecific indicator of the structural integrity of the tissue being imaged.



- An extension of MT, the magnetization transfer ratio (MTR) has been used in neuroradiology to highlight abnormalities in brain structures.

### USES :

- Multiple Sclerosis
- Stroke ,Ischemic vascular dementia
- CNS tuberculosis
- Brain tumours
- Mild head trauma
- Frontal lobe epilepsy
- Muscular dystrophy ,
- Alzheimer's disease .



*THANKYOU*

